



ONCOLOGY

Epithelioid angiosarcoma of the masseter muscle: a rare clinicopathological diagnosis

Anitya Srivastava¹, Ruchi Nagpal², Harshi Dhingra³, Asif Baliyan⁴

1) Department of ENT, Dr. Ram Manohar Lohia Institute of medical sciences, Lucknow, Uttar Pradesh, India

2) Department of Pathology, Bhaskar Medical College and Hospital Hyderabad, Andhra Pradesh, India

3) Department of Pathology, Adesh Institute of Medical Sciences and Research, Bathinda, Punjab, India

4) Focus Imaging and Research Centre Pvt Ltd-Laboratory Medicine Division, New Delhi, India

Abstract

Epithelioid angiosarcoma (EA) is a subtype of angiosarcoma which is a rare tumor of endothelial origin. Here, we report a case of 15-year-old boy who presented with soft tissue mass lesion in the parotid region mimicking as a benign parotid tumor. Cytology was suggestive of inflammatory swelling. Patient underwent superficial parotidectomy along with the wide excision of the swelling. On histopathology, it was diagnosed as EA. To the best of our knowledge this is the first case report of epithelioid angiosarcoma of the masseter.

Keywords: epithelioid angiosarcoma, masseter muscle, parotid, radiotherapy, chemotherapy

Introduction

EA is a highly aggressive endothelial cell malignancy most commonly arising in the deep soft tissues of the extremities [1]. It was described for the first time by Weiss et al. [2] as a rare vascular neoplasm predominantly affecting the adults, accounting for less than 2% of soft tissue sarcomas and less than 1% of head and neck malignancies [3]. Its rarity and the consequent low index of suspicion makes the clinical diagnosis challenging. EA is a rare entity in the pediatric age group presenting with a diagnostic challenge. These lesions are not confined within distinct borders but extend beyond making it difficult for the surgeon to excise the complete lesion [4]. It is considered as one of the most aggressive neoplasm with high rates of recurrence and early metastasis with poor prognosis. The histological picture along with immunoreactivity for cytokeratins (CK) and epithelial membrane antigen (EMA) may be confusing and hence can lead to misdiagnosis [5]. We describe a unique case of a 15-year-old boy who presented with soft tissue swelling in the parotid region. Histologically the lesion was reported as EA of the masseter,

though it was completely confined within the distinct capsule. The location and confinement of the tumor within the capsule are highly rare and unique.

Case report

A 15-year old boy presented to us with the complaints of gradually progressive painless swelling in the left parotid region for one year. There was no history of facial nerve involvement, nor of radiation exposure. No history of smoking, alcohol consumption or any chronic disease was present. There was no family history of malignancy. General examination was normal. On local examination, single 3x2 cm, well defined, non tender, firm mass was palpated in the left parotid region in front of the left angle of mandible with no local rise in temperature and the skin over the swelling and surrounding region was normal (Figure 1a). There was no scar, sinus or fistula present over the swelling. Swelling was bi-digitally palpable and facial nerve examination was normal. Patient underwent CT scan which revealed a hypodense lesion occupying the left masseter muscle whereas with contrast, the lesion showed intense enhancement (Figure 1b). He was then subjected to Fine

DOI: 10.15386/mpr-1751

Manuscript received: 31.05.2020

Received in revised form: 07.07.2020

Accepted: 27.07.2020

Address for correspondence:
ruchi2001@gmail.com

This work is licensed under a Creative Commons Attribution-NonCommercial-NoDerivatives 4.0 International License

needle aspiration cytology (FNAC) which was suggestive of inflammatory pathology. Although FNAC reported inflammatory pathology, clinically a malignancy was suspected and hence patient was planned for superficial parotidectomy of the left parotid gland along with wide excision of the swelling involving masseter muscle and preauricular lymph node clearance. Intraoperatively, approximately 4x4 cm mass from the deep intra masseteric region was excised along with the superficial lobe of the left parotid gland. Facial nerve along with all its branches were preserved (Figure 1c). Lymph nodes were also cleared from the preauricular region and complete specimen was sent for histopathological examination. Grossly, three specimens were received and examined. The largest measuring 4.7 x 3 x 0.8 cm was identified as salivary gland whose cut section showed normal lobular architecture. Globular tumor mass measured 3.5 x 2.5 x 2.5 cm, it appeared encapsulated with smooth outer surface and solid tan brown congested cut surface. Separate fibro-fatty tissue with attached part of the muscle measured 2 x 1.5 x 0.5 cm. Sections from the globular mass showed pseudo-encapsulated tumor composed of tumor cells arranged in sheets and interspersed foci of necrosis, congestion, hemorrhage and cystic degeneration (Figure 2a-

b). Tumor cells were epithelioid to plump spindle shaped with a rich network of small caliber blood vessels as well as compressed to dilated vascular spaces lined by similar plump cells having large, moderately pleomorphic round to ovoid nuclei, coarse chromatin, prominent nucleoli and moderate to abundant eosinophilic cytoplasm (Figure 2c). Six to eight mitotic figures/10 HPF were seen. The resected specimen had clear margins. Six lymph nodes were dissected from the specimen and all of them were clear with no extra nodal extension. Salivary gland and all the lymph nodes were free from tumor. Keeping the differentials in mind, a panel of immunohistochemistry (IHC) markers was ordered. FLI-1 was positive (Figure 2d), S-100 was focal positive and Ki-67 proliferation index was 30-40%. Markers such as CD-34, EMA, Pan-CK, Desmin, HMB-45, CD-30, Synaptophysin, Melan-A and CD-117 were all negative. Thus the final diagnosis of EA, FNCLCC grade: Grade 2 (Score 5) was rendered. Postoperatively, the patient was healthy and was advised adjuvant radiotherapy. The patient was on follow up for six months and was doing well with no local or systemic complications. Later, he was referred to a center dedicated for radiotherapy and chemotherapy.

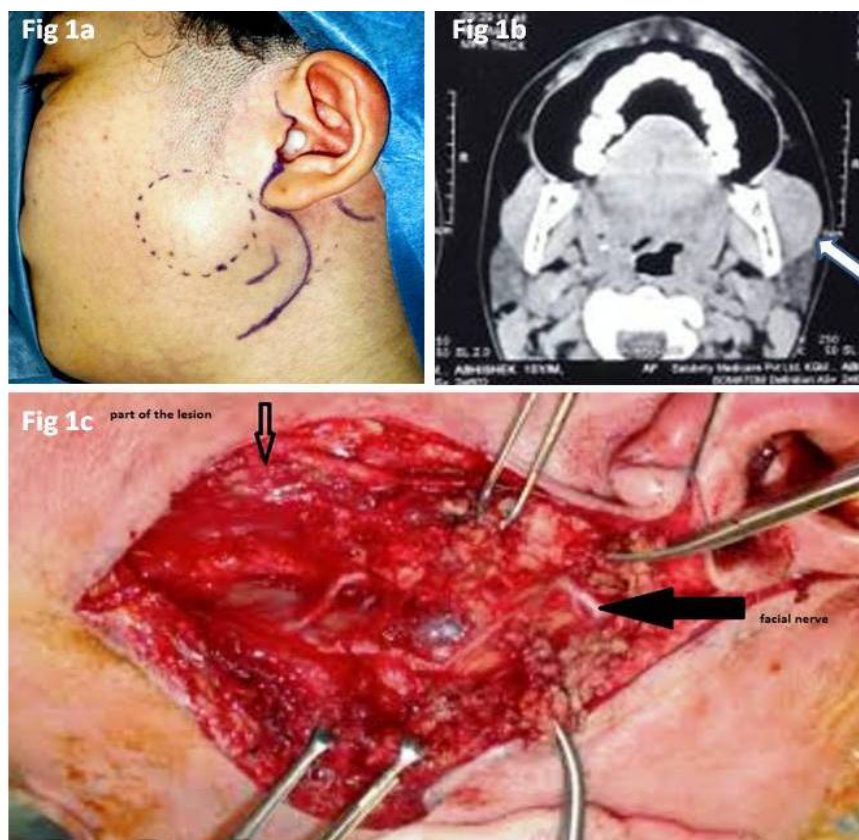


Figure 1. (a) Markings showing the mass and the modified Blair's incision in the preauricular region. (b): CT scan showing hypodense lesion occupying the left masseter muscle. (c) Intraoperative picture showing facial nerve and its branches after superficial parotidectomy with small nodular mass in the masseter muscle.

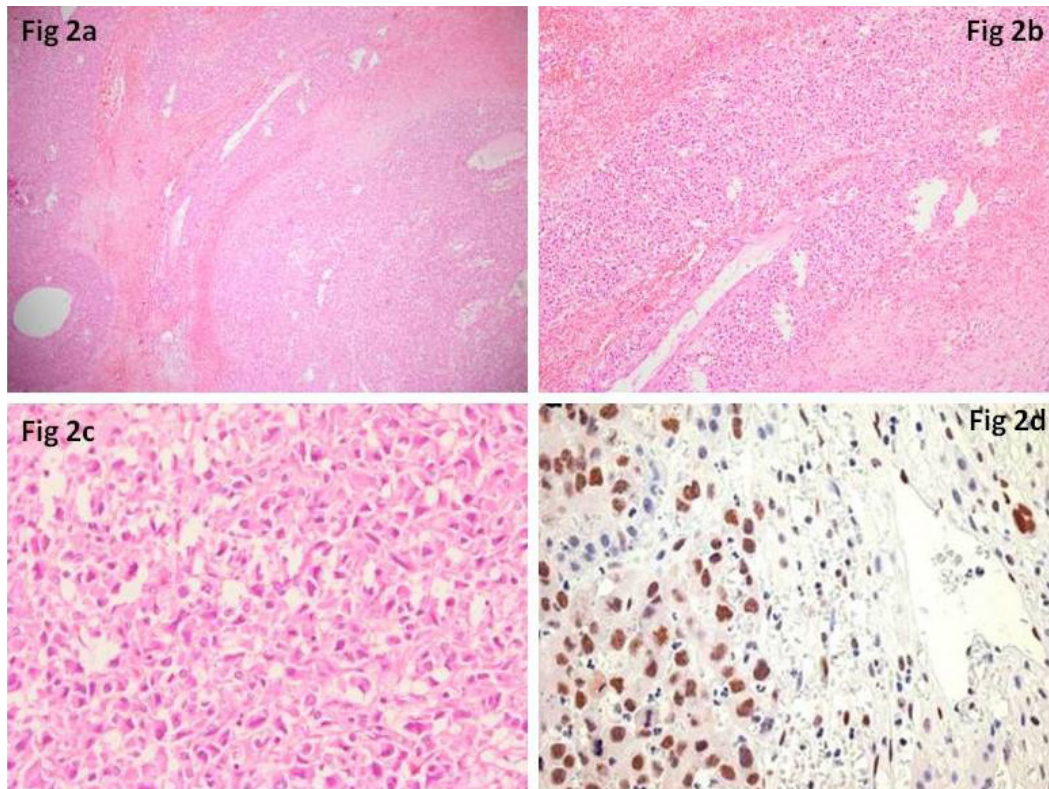


Figure 2. (a,b) Tumor cells are arranged in sheets with interspersed foci of necrosis, congestion, haemorrhage, cystic degeneration and large blood vessels (H&E stain, 10x and 20x respectively). (c) Epithelioid to plump spindle shaped tumor cells having large, moderately pleomorphic round to ovoid nuclei, coarse chromatin, moderate to abundant eosinophilic cytoplasm with few mitotic figures and rich network of small caliber blood vessels are noted (H&E stain, 40x). (d) Immunohistochemistry shows nuclear positivity for FLI-1.

Discussion

Angiosarcomas (AS) are rare malignancies of endothelial cell origin, accounting for less than 1% of all head and neck malignancies [3], ranging histologically from well differentiated tumors with variable endothelial atypia to high grade spindle cell malignancies yielding minimal clues to their cell of origin. EA is a subtype of angiosarcoma which is a rarest subtype as well as highly aggressive but its etiology is still ambiguous. However, previous irradiation, toxic chemical exposure, the use of Thorotrast contrast media, implanted Dacron vascular grafts, arteriovenous fistulae and chronic lymphedema have been identified as specific risk factors [4]. EA is extremely rare in pediatric age group. It generally affects men in the age group of sixth to seventh decade [1,4]. Case studies [4,5] have shown that pediatric EA are more aggressive than the adult EA. Pediatric EA are either classified as intermediate or high grade and can also evade peripheral tissues. It shows affinity for metastasis. It usually manifests with the pain and the presence of a focal mass, followed by significant weight loss, fever and myalgia [4]. Our patient was 15-year old with no significant history of any of these risk factors and presented with just focal mass lesion. Radiologically,

EA has no specific characteristic features but exhibits non-specific imaging signs of malignancy. Strong enhancement is typically seen following contrast agent administration, suggestive of vascular origin of the tumor [6].

The gross pathologic findings in EA differ from those of typical angiosarcomas as these tend to form hemorrhagic, spongy masses due to their inherent vascular nature [7]. These lesions typically have indistinct borders and commonly extend beyond their gross confines making it difficult for the surgeon to ensure a complete resection. In our case, the lesion was well circumscribed with distinct borders. It was located in the masseter muscle encroaching the tail of Parotid gland. Histologically, it is characterized by the proliferation of cells with a remarkable epithelioid morphology, exhibiting a predominantly sheet-like growth pattern and occasionally, pseudoglandular or alveolar arrangement. The large polygonal cells display significant pleomorphism and cytological atypia with irregular nuclear membrane, centrally or slightly eccentrically placed vesicular nuclei and prominent nucleoli. Cystically dilated spaces filled with blood, cytoplasmic vacuoles with entrapped erythrocytes, abundant and abnormal mitosis and necrosis are the frequent findings [4,8]. Our patient

had a similar histopathological picture, showing necrosis, congestion, hemorrhage and cystic degeneration. Tumor cells were epithelioid to plump spindle shaped with a rich network of small caliber blood vessels. IHC is extremely helpful in the diagnosis of EA. Although highly nonspecific, vimentin is almost invariably positive in these tumors. Cytokeratin (CK) may be positive in some cases of EA. Markers of endothelial cell origin used most often include CD31, CD34, Factor VIII-related antigen and FLI-1 [9]. CD31 is the single best marker of endothelial differentiation in routinely fixed tissues and is helpful in differentiating EA from amelanotic melanoma and undifferentiated carcinoma, particularly if Factor VIII-related antigen is negative [10]. Ki-67 with MIB-1 is usually greater in all subtypes of AS, and high Ki-67 value is associated with a worse prognosis. Our case showed positivity for FLI-1. Ki-67 proliferation index was 30-40%. CD-34, EMA, Pan-CK, Desmin, HMB-45, CD-30, Synaptophysin, Melan-A, CD-117 were negative.

On the morphological basis, EA poses diagnostic challenges in relation to other lesions, including epithelioid hemangioma, epithelioid hemangioendothelioma (EHE), metastatic carcinoma, metastatic melanoma, lymphoma, epithelioid sarcoma, and many sarcomas with epithelioid features. Epithelioid hemangioma usually affects younger patients. These are well-circumscribed lesions with characteristic well-formed vessels but lack severe nuclear atypia, signifying its benign nature. When compared to the high-grade EA, EHE usually presents with intracytoplasmic lumina with erythrocytes, and stromal changes (chondroid or hyalinized stroma), but lacks well-formed vascular channels and have less marked nuclear atypia. However, both EHE and EA originate from endothelial cells, and therefore morphology and immunophenotypes overlap. The characteristic fusion genes WWTR1-CAMTA1 have been reported mainly in EHE as compared with other vascular tumors and may help in their differentiation [4,11]. Poorly differentiated carcinoma can be excluded by negative staining for vascular markers (CD31, CD34, FLI-1, etc.) and positivity for CK. CK is also positive in one third cases of EA and hence cannot be used as an absolute discriminant between angiosarcoma and carcinoma. However, proper morphological evaluation, particularly for vascular differentiation helps exclude these lesions [4]. Negative staining for S-100 and HMB-45 helps exclude melanoma. Epithelioid sarcomas, particularly the proximal-type variant (PES), composed of large epithelioid cells with prominent nucleoli and cytological atypia may look morphologically identical to EA but these are typically positive for vimentin, CK, epithelial membrane (EMA) and CD34 but negative for markers of endothelial cell origin including CD31, FLI-1 and Factor VIII-related antigen [12]. Anaplastic large-cell lymphoma, epithelioid rhabdomyosarcoma, and epithelioid variants of malignant nerve sheath tumors can be excluded by negative staining for endothelial cell markers by IHC.

Though there is no standard treatment protocol for angiosarcoma, surgical resection with adjuvant radiotherapy is the recommended one which was followed in our case. Some studies [1,5,13] showed that paclitaxel has antiangiogenic properties which can be used in the local control of EA. Studies like Fata et al. [13], Hart et al. [1] and Mullins et al. [3] have shown the efficacy of paclitaxel, but there is no ongoing antiangiogenic therapy which can be stated as the gold standard. Adjuvant radiotherapy shows local control and improves overall survival. Pawlik et al. [14] reported that patients who had received adjuvant radiotherapy along with the surgical resection had better survival rate. Radiotherapy has its limitations and poses a greater risk in children. New modalities like immunotherapy can be considered but thorough research analysis is required. The prognosis of EA is usually unfavorable as it grows rapidly with metastasis to lung, bone soft tissue, lymph nodes and brain. Most patients die within six months after diagnosis though our patient was healthy with no such signs of complications on regular follow up. Prognostic factors include tumor site, size, stage, cellularity, pleomorphism and mitotic activity. Poor prognostic indicators include bleeding, pain and lesions greater than five centimeters in size. In this case, metastatic lesions were not found and the lesion was pseudo-encapsulated which was in itself a rare finding.

Conclusion

To the best of our knowledge this is the first case report of EA of the masseter muscle. Knowledge of this subtype of angiosarcoma, its clinicopathological and immunohistochemical picture is essential to prevent misdiagnosis. Although no current treatment protocol for the management of EA is available, surgical resection with negative margins and adjuvant radiotherapy are the current mainstay. Further studies are required for designing a better and more efficacious treatment protocol so that the associated disease morbidity and mortality could be reduced.

References

1. Hart J, Mandavilli S. Epithelioid angiosarcoma: a brief diagnostic review and differential diagnosis. *Arch Pathol Lab Med.* 2011;135:268-272.
2. Weiss SW, Ishak KG, Dail DH, Sweet DE, Enzinger FM. Epithelioid hemangioendothelioma and related lesions. *Semin Diagn Pathol.* 1986;3:259-287.
3. Mullins B, Hackman T. Angiosarcoma of the Head and Neck. *Int Arch Otorhinolaryngol.* 2015;19:191-195.
4. Wu J, Li X, Liu X. Epithelioid angiosarcoma: a clinicopathological study of 16 Chinese cases. *Int J Clin Exp Pathol.* 2015;8:3901-3909.
5. Ayadi L, Khabir A. Pediatric angiosarcoma of soft tissue: a rare clinicopathologic entity. *Arch Pathol Lab Med.* 2010;134:481-485.

6. Wenger DE, Wold LE. Malignant vascular lesions of bone: radiologic and pathologic features. *Skeletal Radiol.* 2000;29:619-631.
7. Branch KD, Smith MT. Epithelioid angiosarcoma: A Case Review. *Pathology Case Reviews* 2008;13:264-268.
8. Deyrup AT, Montag AG. Epithelioid and epithelial neoplasms of bone. *Arch Pathol Lab Med.* 2007;131:205-216.
9. Stavridis S, Mickovski A, Filipovski V, Banev S, Dohcevic S, Lekovski L. Epithelioid angiosarcoma of the adrenal gland. Report of a case and review of the literature. *Macedonian Journal of Medical Sciences.* 2010;3:388-394.
10. Bacchi CE, Silva TR, Zambrano E, Plaza J, Suster S, Luzar B, et al. Epithelioid angiosarcoma of the skin: a study of 18 cases with emphasis on its clinicopathologic spectrum and unusual morphologic features. *Am J Surg Pathol.* 2010;34:1334-1343.
11. Cheng X, Yang G, Liu J, Liu F. Epithelioid angiosarcoma of the chest wall with atypical morphology: report of one case. *Int J Clin Exp Pathol.* 2019;12:3944-3948.
12. Zevallos-Giampietri EA, Barrionuevo C. Proximal-type epithelioid sarcoma: report of two cases in the perineum: differential diagnosis and review of soft tissue tumors with epithelioid and/or rhabdoid features. *Appl Immunohistochem Mol Morphol.* 2005;13:221-230.
13. Fata F, O'Reilly E, Ilson D, Pfister D, Leffel D, Kelsen DP, et al. Paclitaxel in the treatment of patients with angiosarcoma of the scalp or face. *Cancer.* 1999;86:2034-2037.
14. Pawlik TM, Paulino AF, McGinn CJ, Baker LH, Cohen DS, Morris JS, et al. Cutaneous angiosarcoma of the scalp: a multidisciplinary approach. *Cancer.* 2003;98:1716-1726.